Acute Lung Injury Patterns other than Diffuse Alveolar Damage

Mary Beth Beasley, MD
Mount Sinai Medical Center
New York, NY

Acute Respiratory Distress Syndrome/Acute Lung Injury

- North American-European Consensus Definition (1994):
  - Acute Respiratory Distress Syndrome (ARDS):
    - PaO2:FiO2 200mmHg or less
    - Wedge pressure less than 18mmHg
    - Bilateral infiltrates radiographically consistent with pulmonary edema
    - No clinical evidence of cardiac failure
  - Acute lung injury (ALI):
    - PaO2:FiO2 of 200-300mmHg
    - Criteria otherwise the same

Updated Berlin definition

Table 1. ARDS Berlin definition.

The Berlin definition of acute respiratory distress syndrome	
Timing	Within 1 week of a known clinical insult or new or worsening respiratory symptoms
Chest imaging[a]	Bilateral opacities — not fully explained by effusions, lobar/lung collapse, or nodules
Origin of edema	Respiratory failure not fully explained by cardiac failure or fluid overload. Need objective assessment (e.g., echocardiography) to exclude hydrostatic edema if no risk factor present
Oxygenation[b]	
Mild	200 mmHg < PaO_2/FIO_2 ≤300 mmHg with PEEP or CPAP ≥5 cmH_2O[c]
Moderate	100 mmHg < PaO_2/FIO_2 ≤200 mmHg with PEEP ≥5 cmH_2O
Severe	PaO_2/FIO_2 ≤100 mmHg with PEEP ≥5 cmH_2O

Abbreviations: CPAP, continuous positive airway pressure; F_IO_2, fraction of inspired oxygen; PaO_2, partial pressure of arterial oxygen; PEEP, positive end-expiratory pressure; [a]Chest radiograph or computed tomography scan; [b]If altitude is higher than 1,000 m, the correction factor should be calculated as follows: [PaO_2/FIO_2×(barometric pressure/760)]; [c]This may be delivered noninvasively in the mild acute respiratory distress syndrome group.

Mortality rate 27% for mild, 32% for Moderate and 45% for severe

J Thorac Dis 2013;5(3):326-334.

Acute/Subacute disease as a pathologic concept

TABLE 2. CATEGORIZATION OF MAJOR IDIOPATHIC INTERSTITIAL PNEUMONIAS

Category	Clinical–Radiologic–Pathologic Diagnoses	Associated Radiologic and/or Pathologic–Morphologic Patterns
Chronic fibrosing IP	Idiopathic pulmonary fibrosis	Usual interstitial pneumonia
	Idiopathic nonspecific interstitial pneumonia	Nonspecific interstitial pneumonia
Smoking-related IP*	Respiratory bronchiolitis-interstitial lung disease	Respiratory bronchiolitis
	Desquamative interstitial pneumonia	Desquamative interstitial pneumonia
Acute/subacute IP	Cryptogenic organizing pneumonia	Organizing pneumonia
	Acute interstitial pneumonia	Diffuse alveolar damage

Am J Respir Crit Care Med Vol 188, Iss. 6, pp 733-748, Sep 15, 2013

Acute lung injury as a pathologic concept

- Meant to emphasize insults resultant from injury at a single point in time
  - DAD represented diffuse injury
  - OP pattern more localized injury
- "Acute lung injury pattern" for overlapping features in small biopsy

ALI as a pathologic concept

- In reality, the vast majority of OP cases do not meet the clinical definition of ARDS
- Still a useful concept when approaching a biopsy from a patient with an illness of short duration

Pathology Associated with Clinical ARDS

- Vast majority of cases will show DAD
- Other patterns may be encountered:
  - Acute Fibrinous and Organizing Pneumonia (AFOP)
  - Acute Eosinophilic Pneumonia (AEP)
  - Diffuse Alveolar Hemorrhage with Capillaritis (DAH-C)

Acute Fibrinous and Organizing pneumonia…where did we start?

Acute Fibrinous and Organizing Pneumonia

A Histologic Pattern of Lung Injury and Possible Variant of Diffuse Alveolar Damage

Mary Beth Beasley, MD; Teri J. Franks, MD; Jeffrey R. Galvin, MD; Bernadette Gochuico, MD; William D. Travis, MD

(*Arch Pathol Lab Med.* 2002;126:1064–1070)

Acute Fibrinous and Organizing Pneumonia (AFOP)

- Originally described in 2002 as a histologic pattern associated with an acute or subacute onset which did not fit with the classic histology of either DAD or OP.
- Original study of 17 cases
  - 15 OLB, 2 autopsies
  - Selected from 114 cases with previous dx of DAD, OP of descriptive dx of fibrinous pneumonia
  - Cases of DAD, OP, EP, acute pneumonia or vasculitis were excluded

Acute Fibrinous and Organizing Pneumonia (AFOP)

- Original study of 17 cases
  - 10 M, 7 F average age 62 (33-78)
  - Average time from symptom onset to bx 19 days (2-60 days)
  - Symptoms: S.O.B. (12), fever (6), cough (4), hemoptysis (2), chest pain (5)
  - Radiology: bibasilar infiltrates most frequent (4), other descriptive reports, 1 unilateral case

Clinical findings

- AFOP was associated with a wide range of potential underlying etiologies
  - Infection (2), collagen vascular (3), exposure (4) drug reaction (2), idiopathic (6)
- Outcome:
  - Nine patients dead of disease
    - Avg time of presentation to death: 29 days (range 6-36 days)
  - 7 patients alive and well
  - 1 patient dead of other causes

Clinical findings

- An optimal therapy was not identified
  - Antibiotics only (7), steroids only(2), steroids after abx failure(3), both at same time(2), diuretics(1), Mech vent only(1).
- No histologic feature correlated with eventual outcome
  - All patients on mechanical ventilation (5) died

AFOP Histology

- Intra-alveolar fibrin balls without hyaline membrane formation
- No significant neutrophils, macrophages or eosinophils
- No granulomas
- Varying degrees of organizing pneumonia which usually retained a central fibrin core
- Patchy distribution (avg 50% airspace involvement range 25-90%); some cases relatively diffuse
- How much fibrin was present was not defined aside from indicating it was the "dominant" finding.
- Mild chronic interstitial inflammation and/or myxoid interstitial fibrosis

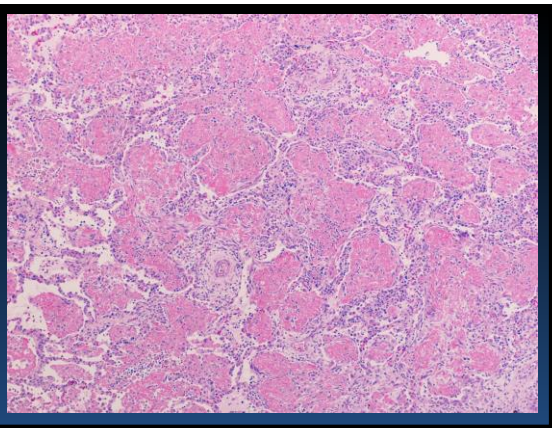

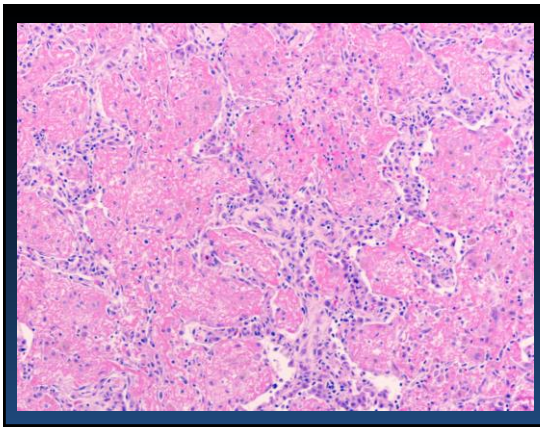

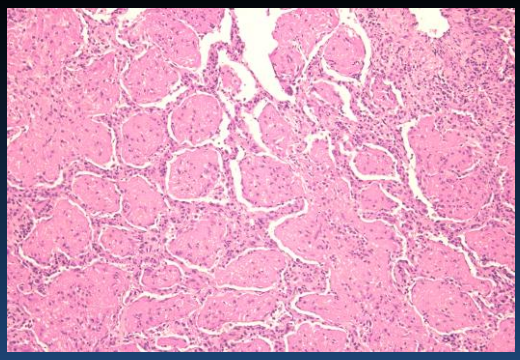

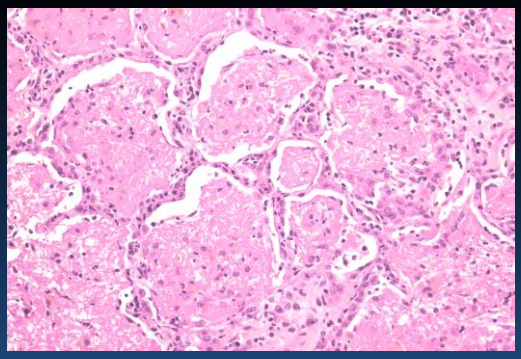

Diagnostic cautions

- Terminology should be used only on large specimens.
  - Intra-alveolar fibrin may occur as a non-specific reaction in association with/adjacent to a number of processes
    - Necrotizing granulomas, malignancy, acute pneumonia/abscess
    - vasculitis
- If any eosinophils are present try to exclude a partially treated eosinophilic pneumonia clinically.
- Intra-alveolar fibrin may be present in cases which otherwise have diagnostic features of DAD>> sampling issue
- Always get microorganism stains…..

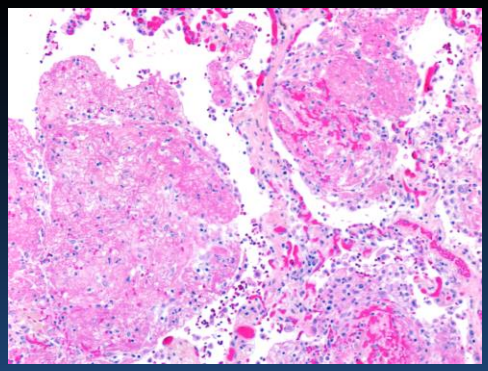

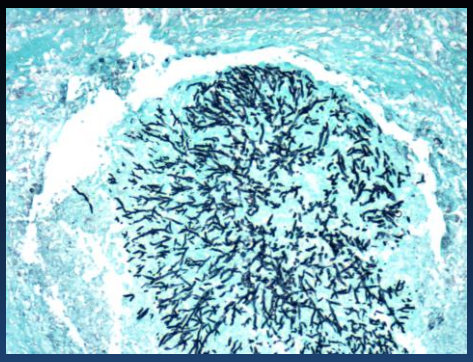

Initial AFOP conclusions..

- **Given the high overall mortality rate is was felt that most cases of AFOP likely represent an under-reported histologic variant of DAD**
- **Did not explain the bimodal outcome/indolent cases with recovery**
  - **?related to EP—histologic overlap; no peripheral blood eosinophilia, inconsistent response to steroids**
- **? Relationship to OP/COP**

AFOP…where are we now? Do we know any more than we did before?

Since 2002…

- Relatively rare:
  - Infection-SARS, H1N1, chlamydia
  - Drugs- amiodarone, abacavir
  - CVD- lupus, anti-EJ, other non-specified
  - Acute hypersensitivity pneumonitis
  - S/p hematopoietic stem cell tx
  - s/p lung transplant
    - Proposed novel form of lung allograft dysfuction
  - Smoking
  - Idiopathic

An Official American Thoracic Society/European Respiratory Society Statement: Update of the International Multidisciplinary Classification of the Idiopathic Interstitial Pneumonias

William D. Travis, Ulrich Costabel, David M. Hansell, Talmadge E. King, Jr., David A. Lynch, Andrew G. Nicholson, Christopher J. Ryerson, Jay H. Ryu, Moisés Selman, Athol U. Wells, Jurgen Behr, Demosthenes Bouros, Kevin K. Brown, Thomas V. Colby, Harold R. Collard, Carlos Robalo Cordeiro, Vincent Cottin, Bruno Crestani, Marjolein Drent, Rosalind F. Dudden, Jim Egan, Kevin Flaherty, Cory Hogaboam, Yoshikazu Inoue, Takeshi Johkoh, Dong Soon Kim, Masanori Kitaichi, James Loyd, Fernando J. Martinez, Jeffrey Myers, Shandra Protzko, Ganesh Raghu, Luca Richeldi, Nicola Sverzellati, Jeffrey Swigris, and Dominique Valeyre; on behalf of the ATS/ERS Committee on Idiopathic Interstitial Pneumonias

Am J Respir Crit Care Med Vol 188, Iss. 6, pp 733-748, Sep 15, 2013

In this document AFOP is mentioned as a "rare histologic pattern" but is not classified as a stand alone IIP

Issues requiring clarification

- How much fibrin do you need to call something AFOP instead of OP/COP?
  - **Type 2 COP (Yoshinouchi, et al 1995)**
- How does it related to other patterns of disease such as OP/COP?
- Do we know anything more than we did about the bi-modal survival and what predicts a good prognosis?

Clinicopathologic features associated with relapse in cryptogenic organizing pneumonia☆,☆☆

Michiya Nishino MD, PhD[a,1], Susan K. Mathai MD[b,1], David Schoenfeld PhD[c], Subba R. Digumarthy MB, BS[d], Richard L. Kradin MD[a,b,e,*]

Human Pathology (2014) **45**, 342–351

Nishino, et al

- 26 patients with "COP"
  - Fibrin evaluation:
    - None
    - Focal (<0.2 cm greatest dimension limited to one histopathologic sections)
    - Multifocal (multiple foci of fibrin involving more than one histopathologic section
    - AFOP-ball like aggregates diffusely filling alveoli

Nishino, et al

- Multifocal fibrin (7 cases) and AFOP (3 cases) had relapse rates of 43% and 100%; regression analysis demonstrated increased relapse with increasing fibrin
  - No fibrin (7 cases) had no relapse
  - Focal fibrin (9 cases) had one relapse
- Patients with lung disease in three zones also had higher relapse

More recently…

A comparison of the pathological, clinical and radiographical, features of cryptogenic organising pneumonia, acute fibrinous and organising pneumonia and granulomatous organising pneumonia

Marc B Feinstein,[1] Shilpa A DeSouza,[1] Andre L Moreira,[2] Diane E Stover,[1] Robert T Heelan,[3] Tunç A Iyriboz,[3] Ying Taur,[1] William D Travis[2]

Feinstein MB, *et al. J Clin Pathol* 2015;**68**:441–447.

Table 1 Pathological abnormalities among OP patients

	All patients	COP	AFOP	GOP	p Value
Number of patients	61	36	10	15	
Fibrin deposition (%)	23 (38)	8 (22)	10 (100)	6 (40)	<0.01
Focal (% of all fibrin deposition)	14 (61)	8 (100)	0 (0)	6 (100)	0.01
Diffuse (% of all fibrin deposition)	9 (39)	0 (0)	10 (100)	0 (0)	<0.01
Type II pneumocyte hyperplasia	34 (56)	18 (50)	10 (100)	7 (47)	n.s.
Focal (% of pneumocyte hyperplasia)	17 (50)	12 (67)	2 (2)	2 (29)	n.s.
Diffuse (% of pneumocyte hyperplasia)	14 (41)	5 (28)	6 (60)	5 (71)	n.s.
Prominent (% of pneumocyte hyperplasia)	3 (9)	1 (6)	2 (20)	0 (0)	n.s.
Lymphoplasmacytic infiltrate	49 (80)	29 (81)	8 (80)	11 (73)	n.s.
Mild (% of lymphoplasmacytic infiltrate)	26 (53)	18 (62)	4 (50)	2 (18)	n.s.
Moderate (% of lymphoplasmacytic infiltrate)	20 (41)	9 (31)	4 (50)	8 (73)	0.01
Severe (% of lymphoplasmacytic infiltrate)	3 (6)	2 (7)	0 (0)	1 (9)	n.s.
Fibrosis	30 (49)	18 (50)	2 (20)	10 (67)	n.s.
Mild (% of fibrosis)	25 (83)	13 (72)	2 (100)	10 (100)	n.s.
Moderate (% of fibrosis)	5 (17)	5 (28)	0 (0)	0 (0)	n.s.
Severe (% of fibrosis)	0 (0)	0 (0)	0 (0)	0 (0)	n.s.

AFOP, acute fibrinous and organising pneumonia; COP, cryptogenic organising pneumonia; GOP, granulomatous organising pneumonia; OP, organising pneumonia.

Table 2 Patient demographics

	All patients	COP	AFOP	GOP	p Value
Number of patients	61	36	10	15	n.s.
Average age (years)	61.5	60.3	59.6	62.6	n.s.
Male sex (%)	35 (57)	25 (69)	4 (40)	6 (40)	n.s.
Caucasian (%)	53 (87)	30 (83)	9 (90)	14 (93)	n.s.
Any history of cancer (%)	43 (70)	25 (69)	10 (100)	8 (53)	0.05
Active cancer (%)	16 (26)	10 (28)	5 (50)	1 (7)	n.s.
Prior radiation (%)	18 (30)	9 (25)	6 (60)	3 (20)	n.s.
Median time from radiation (months)	13.5	7.9	4.5	143	n.s.
Prior chemotherapy (%)	27 (44)	15 (42)	8 (80)	4 (27)	0.03
Median time from chemotherapy (months)	3.0	2.7	2.5	76.5	n.s.
Ever smoker	36 (59)	19 (53)	5 (50)	12 (80)	n.s.
Ex-smoker (% of all smokers)	32 (89)	16 (84)	4 (80)	12 (100)	n.s.
Active smoker (% of all smokers)	4 (11)	3 (16)	1 (20)	0 (0)	n.s.
Median pack-years	30	45	30	25.5	n.s.
Any respiratory symptom (%)	32 (52)	20 (56)	6 (60)	6 (40)	n.s.
Respiratory failure (%)	3 (5)	1 (3)	2 (20)	0 (0)	n.s.
Medication prescribed (%)*	15 (25)	10 (28)	3 (30)	2 (13)	n.s.
Steroids (% of all medications)	14 (93)	9 (90)	3 (100)	2 (100)	n.s.
Macrolides (% of all medications)	4 (27)	2 (20)	0	2 (100)	n.s.
Azathioprine (% of all medications)	3 (20)	3 (20)	0	0	n.s.
Death (%)	14 (23)	9 (25)	4 (40)	1 (7)	n.s.
Death due to organising pneumonia (% of all deaths)	1 (7)	1 (11)	0 (0)	0 (0)	n.s.

*Seven patients received multiple medication forms (five with COP, two with GOP).
AFOP, acute fibrinous and organising pneumonia; COP, cryptogenic organising pneumonia; GOP, granulomatous organising pneumonia.

444 Feinstein MB, *et al*. *J Clin Pathol* 2015;68:441–447. doi:10.1136/jclinpath-2014-202626

Table 3 Radiographical abnormalities among OP patients

	All patients	COP	AFOP
Number of patients	61	36	10
Location			
Central (%)	1 (2)	1 (3)	0 (0)
Peripheral (%)	46 (75)	26 (72)	7 (70)
Diffuse (%)	14 (23)	9 (25)	3 (30)
Character of radiographical change*			
Nodule or mass (%)	54 (89)	32 (89)	7 (70)
Consolidation (%)	22 (36)	13 (36)	5 (50)
Ground-glass (%)	11 (18)	9 (25)	2 (20)
Air bronchograms (%)	16 (26)	8 (22)	5 (50)
Other findings*			
Adenopathy			
Mediastinal (%)	9 (15)	5 (14)	2 (20)
Hilar (%)	3 (5)	2 (6)	0 (0)
Honeycombing (%)	2 (3)	0 (0)	0 (0)
Pleural effusion (%)	8 (13)	6 (17)	2 (20)
Cavitation (%)	2 (3)	1 (3)	1 (10)
Reverse halo sign (%)	1 (2)	0 (0)	1 (10)
Bronchiectasis (%)	9 (15)	5 (14)	2 (20)
Fibrosis (%)	4 (7)	1 (3)	1 (10)

Feinstein, et al

- 10 new cases of AFOP
- Cases had 50% or more fibrin
- All recovered including 2 with respiratory failure; 4 asymptomatic patients
  - ? Earlier disease
  - ? Somehow related to hx of chemo or prior cancer

Conclusions/Future directions

- Is AFOP a "stand alone" IIP or just a pattern of lung injury?
  - More critical to recognize the significance of it when you see it
- ?How much fibrin do you need
  - More seems to be worse but..
  - Needs to be evaluated in context of other parameters—disease extent, PFT's etc
  - Conclusive predictors of poor prognosis still unclear

Acute Eosinophilic Pneumonia

Eosinophilic lung disease

Box 1.
Classification of the eosinophilic pneumonias in clinical practice

Eosinophilic pneumonias of unknown cause
- Solitary idiopathic eosinophilic pneumonias
  - Idiopathic chronic eosinophilic pneumonia
  - Idiopathic acute eosinophilic pneumonia
- Eosinophilic pneumonia in systemic syndromes
  - Churg-Strauss syndrome
  - Idiopathic hypereosinophilic syndromes (lymphocytic or myeloproliferative variant)

Eosinophilic pneumonias of known cause
- Allergic bronchopulmonary aspergillosis and related syndromes (including bronchocentric granulomatosis)
- Eosinophilic pneumonias of parasitic origin
- Eosinophilic pneumonias of other infectious causes
- Drug-induced eosinophilic pneumonias

Other pulmonary syndromes with possible usually mild eosinophilia
- Organizing pneumonia, asthma, idiopathic pulmonary fibrosis, Langerhans cell histiocytosis, malignancies, and so forth

Eosinophilic Lung Diseases
Vincent Cottin, MD, PhD[a,b], Jean-François Cordier, MD[a,b]
Immunology and Allergy Clinics of North America
Volume 32, Issue 4, November 2012, Pages 667–698

Eosinophilic pneumonia General Considerations

- >25% BAL eosinophils in BAL, preferably >40%
- Peripheral blood esoinophilia >1000/mm3, preferably >1500/mm3
  - May be absent in acute EP or in patients receiving steroid rx.
- Most cases idiopathic
  - Rule out fungus/parasites, drug reaction, toxic exposure

Idiopathic chronic EP

- Initially described by Carrington, et al
- Subacute disease, 2:1 female: male ratio; average age 45
- Prior asthma in 2/3
- Half with prior atopic symptoms
- Most patients are non-smokers

Idiopathic chronic EP

- Symptoms-Dyspnea, cough; hemoptysis rare
- Fatigue, malaise, fever, night sweats,weight loss
- Symptom duration usually 2-4 weeks
- Imaging
  - Bilateral alveolar infiltrates with ill-defined margins
    - CT-Confluent consolidations and ground glass opacities
    - Spontaneous migration in 25%
    - Subpleural and upper lobe predominance

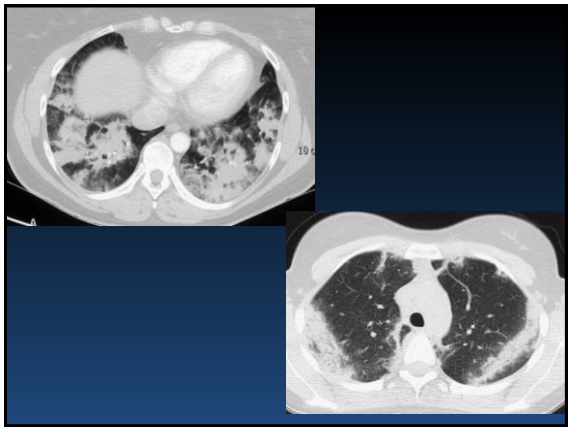

Idiopathic Chronic EP summary

Box 2
Diagnostic criteria for ICEP

1. Diffuse pulmonary alveolar consolidation with air bronchogram and/or ground-glass opacities at chest imaging, especially with peripheral predominance
2. Eosinophilia at BAL differential cell count ≥40% (or peripheral blood eosinophils ≥1000/mm^3)
3. Respiratory symptoms present for at least 2 to 4 weeks
4. Absence of other known causes of eosinophilic lung disease (especially exposure to drug susceptible to induce pulmonary eosinophilia).

Eosinophilic Lung Diseases
Vincent Cottin, MD, PhD[a,b] ▲ ✉, Jean-François Cordier, MD[a,b]
Immunology and Allergy Clinics of North America
Volume 32, Issue 4, November 2012, Pages 557–586

Eosinophilic pneumonia

- Intra-alveolar fibrin, macrophages, abundant eosinophils, eosinophil microabscess
- +/- organizing pneumonia
- sensitive to steroids, relapse not uncommon

Eosinophilic pneumonia

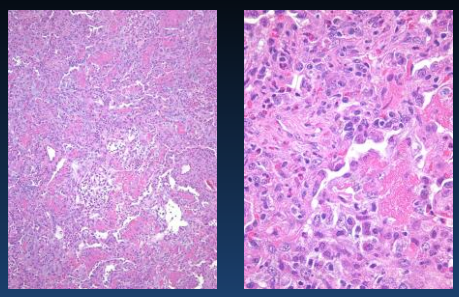

Eosinophilic pneumonia

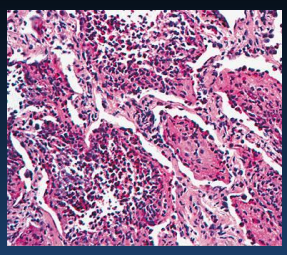

Acute Eosinophilic Pneumonia

- **Some cases of eosinophilic pneumonia present with fulminate respiratory failure**
- **May not have peripheral blood eosinophilia as seen in chronic EP**
- **Typically do not have asthma history**

AEP

- Typically occurs in previously healthy adults
- Mean age 30 years
- Male predominance
- Two thirds of patients are smokers
  - Triggering role of recent initiation of tobacco smoking, change in smoking habits or restarting to smoke
  - May also develop after other non-specific exposures

AEP

- Acute onset of dyspnea, fever, thoracic pain, myalgia
- Frequent acute respiratory failure
- Time of symptoms to hospital admission usually less than 7 days
- Blood eosinophil counts usually normal at presentation but may increase later
- BAL eosinophilia reported at 37-54%--key to clinical dx

AEP Imaging

- CXR-Bilateral infiltrates with mixed alveolar and interstitial opacities
- CT- poorly definied nodules/ground glas attenuation, airspace consolidationseptal thickening, Pleural effusion in up to 75%.

Idiopathic AEP summary

Box 3
Diagnostic criteria for IAEP

1. Acute onset with febrile respiratory manifestations (≤1 month, and especially ≤7 days duration before medical examination)
2. Bilateral diffuse infiltrates on imaging
3. Pa_{O_2} on room air ≤60 mmHg (8 kPa), or Pa_{O_2}/Fi_{O_2} ≤300 mmHg (40 kPa), or oxygen saturation on room air <90%
4. Lung eosinophilia, with ≥25% eosinophils at BAL differential cell count (or eosinophilic pneumonia at lung biopsy when done)
5. Absence of determined cause of acute eosinophilic pneumonia (including infection or exposure to drugs known to induce pulmonary eosinophilia). Recent onset of tobacco smoking or exposure to inhaled dusts may be present.

Eosinophilic Lung Diseases

Vincent Cottin, MD, PhD[a,*], Jean-François Cordier, MD[a,b]

Immunology and Allergy Clinics of North America

Volume 32, Issue 4, November 2012, Pages 567–586

Acute EP Histology

- Acute EP has hyaline membranes essentially identical to those in DAD
- Histologic features of classic/chronic EP may or may not be present:
  - Intra-alveolar fibrin and macrophages
  - Organizing pneumonia
- Eosinophils present

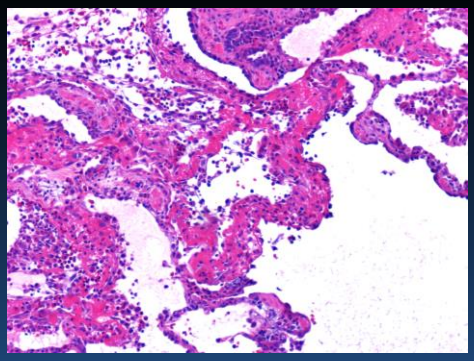

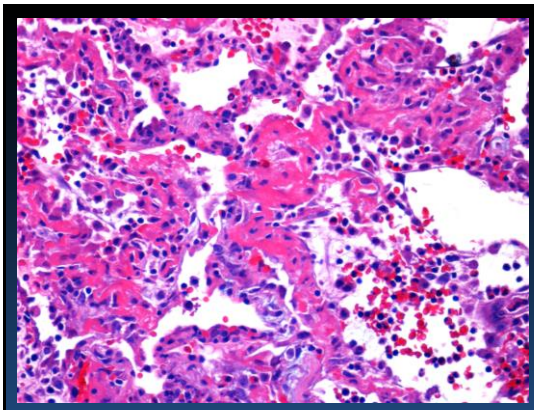

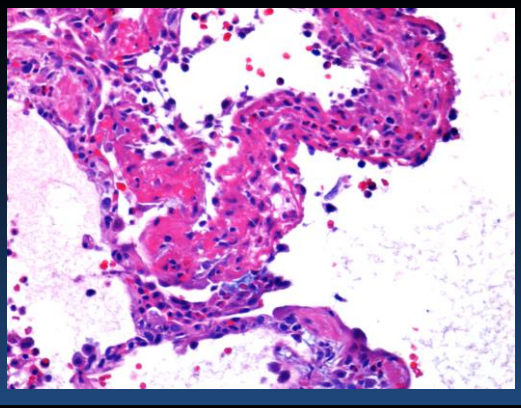

Acute Eosinophilic Pneumonia

- Eosinophils should be sought in all cases of DAD as AEP is exquisitely sensitive to steroid therapy
- Relapse is infrequent after proper therapy in contrast to chronic EP.

Conclusions

- Histologic patterns other than DAD should be kept in mind in a patient presenting with clinical ARDS
- AFOP is a histologic pattern of acute lung injury potentially associated with a variety of potential etiologies
  - Refinement of diagnostic criteria in relationship to OP/COP in particular is needed
- Eosinophils should be sought in all cases of DAD in particular

THANK YOU!!!